

Primary Cutaneous Lymphoma

PRIMARY CUTANEOUS LYMPHOMA

Key points

- ▶ These are lymphomas that occur in the skin, with no evidence of systemic disease at diagnosis.
- ▶ Accurate diagnosis is essential as the prognosis can change from excellent to rapidly fatal, depending on the type of lymphoma.
- ▶ Expert review of biopsies is recommended.
- ▶ It is essential to distinguish between primary cutaneous lymphoma and secondary cutaneous involvement by systemic lymphoma as the treatment and prognosis can be stark.
- ▶ Referral for specialist review is required.

After gastrointestinal lymphoma, primary cutaneous lymphomas (PCLs) are the second most commonly occurring extranodal non-Hodgkin lymphoma. Whilst they are relatively rare (estimated at 1 in 100,000 yearly), some can have an aggressive, rapid clinical course and accurate diagnosis is essential.

They are a heterogeneous group of lymphomas that develop in the skin, as opposed to secondary cutaneous involvement by systemic lymphoma. Although some share histological, immunophenotypic and genetic similarities with their systemic counterparts, many are clinically and histologically distinct entities with quite different prognoses and therapeutic implications. As such, distinguishing between primary and secondary cutaneous lymphomas is extremely important, particularly for the more indolent PCLs that do not require aggressive treatment. Referral for specialist review is essential as formal clinical staging is required to distinguish between the two.

As with systemic lymphoma, the classification of PCL is constantly being modified by advances in molecular pathology. These advances allow more accurate classification and diagnosis, particularly in entities with overlapping morphology but very different clinical courses. The latest (2016) revision of the WHO classification of lymphoid neoplasms* includes some changes to pre-existing PCL entities and also lists a new provisional entity (*Table 2 overleaf*). This table does not include extracutaneous lymphomas that frequently secondarily involve the skin.

Of the PCLs, approximately 65% are cutaneous T-cell lymphomas (CTCLs), 25% are cutaneous B-cell lymphomas and 10% are uncommon immature haematopoietic forms. Primary CTCLs can be divided into those with indolent or aggressive behaviour (*Table 1 below*). The indolent lymphomas often remain localised to the skin for many years but systemic spread may eventually occur with some. The aggressive lymphomas usually present with extensive skin involvement at the time of diagnosis. Systemic symptoms and rapid spread to other organs are also common in the aggressive lymphomas, with the exception of Sézary syndrome. In these cases, distinguishing between a PCL and secondary skin involvement is less important than for the indolent lymphomas.

Table 1

Primary CTCLs with indolent behaviour

Mycosis fungoides and variants

Primary cutaneous CD30+ lymphoproliferative disorder (primary anaplastic large cell lymphoma and lymphomatoid papulosis)

Subcutaneous panniculitis-like T-cell lymphoma

Primary cutaneous CD4+ small/medium T-cell lymphoproliferative disorder (provisional entity)

Primary cutaneous acral CD8+ T-cell lymphoma (provisional entity)

Primary CTCLs with aggressive behaviour

Sézary syndrome

Extranodal NK/T-cell lymphoma, nasal type

Primary cutaneous peripheral T-cell lymphoma, unspecified

Primary cutaneous aggressive epidermotropic CD8+ T-cell lymphoma (provisional entity)

Primary cutaneous gamma/delta-positive T-cell lymphoma

Table 2: Primary cutaneous lymphomas in the 2016 Revision of the WHO classification of lymphoid neoplasms

CUTANEOUS T-CELL AND NK-CELL LYMPHOMAS

Mycosis fungoides (MF)	Mycosis fungoides variants and subtypes
Sezary syndrome	
Adult T-cell leukaemia/lymphoma	
Primary cutaneous CD30+ lymphoproliferative disorders	Primary cutaneous anaplastic large cell lymphoma Lymphomatoid papulosis
Subcutaneous panniculitis-like T-cell lymphoma	
Extranodal NK/T-cell lymphoma, nasal type	
Primary cutaneous γ/δ T-cell lymphoma	
Primary cutaneous peripheral T-cell lymphoma, unspecified	
Primary cutaneous peripheral T-cell lymphoma, provisional entities	Primary cutaneous aggressive epidermotropic CD8+ T-cell lymphoma Primary cutaneous CD4+ small/medium T-cell lymphoproliferative disorder Primary cutaneous acral CD8+ T-cell lymphoma (new)

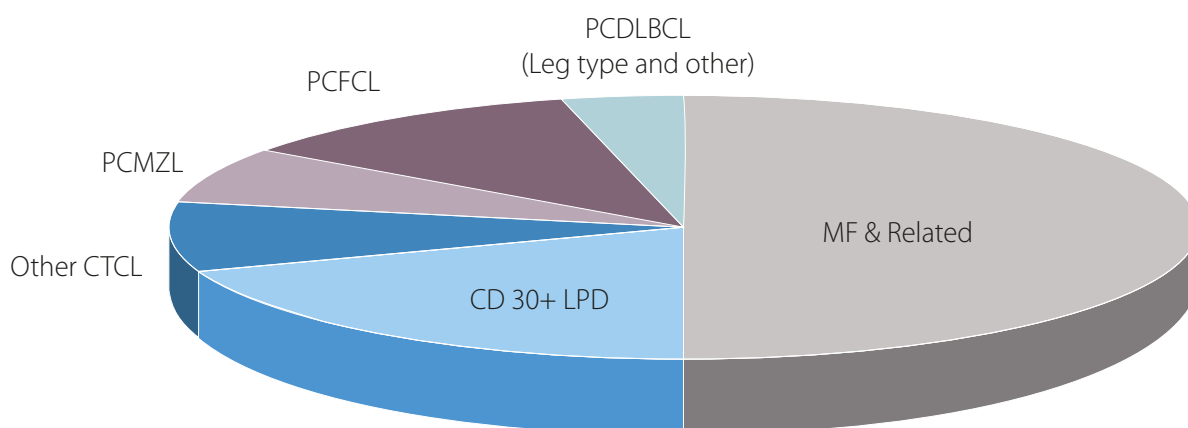
CUTANEOUS B-CELL LYMPHOMAS

	Marginal zone B-cell lymphoma (PCMZL)
	Follicle center lymphoma (PCFCL)
	Diffuse large B-cell lymphoma, leg type (PCLBCL)

BLASTIC PLASMACYTOID DENDRITIC CELL NEOPLASM

(formerly CD4+/CD56+ hematodermic neoplasm or blastic NK cell lymphoma)

Fig 1: Relative Frequency of Cutaneous Lymphoma Classified by WHO-EORTC Classification



Reference:

*Swerdlow S et al. The 2016 revision of the World Health Organisation classification of lymphoid neoplasms. Blood. 2016; 127(20):2375-2390.

Dr Debra Norris FRCPA; MBBS (HONS)
Pathologist in Charge - Histology
Haematopathologist (member EAHP),
Dermatopathologist
P: (07) 3121 4444
E: DNorris@qml.com.au

Dr Natalie Scott-Young BSc(Hons), MBBS,
FRCPATH (UK)
Consultant Dermatopathologist
P: (07) 3121 4444
E: Natalie.Scottyoung@qml.com.au

Dr David Guard BSc MBBS FRCPA
Consultant Histopathologist
P: (07) 3121 4444
E: DrDavid.Guard@qml.com.au