

Benign Melanocytic Proliferations and Naevi

Melanocytic proliferations and naevi often require careful clinical and/or pathological assessment to exclude malignancy. This is best achieved by accurate classification of the lesion into a recognised diagnostic category. These major recognised diagnostic categories are discussed below.

FRECKLE (EPHELIS)

A freckle (ephelis) is an area of increased melanin production without an increase in melanocyte numbers. These will often fade in the absence of UV exposure.

LENTIGO

In contrast, a lentigo shows an increase of melanocytes in linear array along the dermoepidermal junction and persists in the absence of UV exposure. Multiple lentiginos are occasionally a component of the rare hereditary syndromes with internal manifestations such as Carney syndrome.

LABIAL MELANOTIC MACULE

Labial melanotic macule is a pigmented macule occurring on the lip that histologically demonstrates increased melanin pigment, normal melanocyte numbers and melanin spill-over into the dermis. Similar lesions may occur on the penis and vulva (genital melanotic macules). These lesions are benign, but tissue diagnosis is of importance to distinguish them from mucosal melanomas, which can demonstrate a deceptively banal clinical appearance.

ACQUIRED MELANOCYTIC NAEVUS

Acquired melanocytic naevi consist of aggregates of benign naevus cells. Junctional naevi consist of nests at the dermoepidermal junction, compound naevi also show dermal naeval cells and intradermal naevi involve the dermis only.

Clinically distinctive variants include the halo naevus, which demonstrates a depigmented halo due to the initiation of inflammatory regression, and the Meyerson naevus, which shows an eczematous halo.

SPITZ NAEVUS

Spitz naevus is a lesion occurring predominantly in children and adolescents, which despite some histologic resemblance to malignant melanoma, behaves in a benign fashion. Clinically, Spitz naevi are usually pink, red or reddish brown papules or nodules that demonstrate rapid growth over 3 to 6 months and then may remain stable for years. The face and lower limbs are common sites.

Histologically, Spitz naevi are composed of plump epithelioid and/or spindle cells, and display symmetry, maturation, Kamino bodies and lack of pagetoid spread of single melanocytes.

Though there are criteria to distinguish Spitz naevi from melanoma, there are some lesions that show features at odds with the classical picture and are designated atypical Spitz naevi/atypical Spitz tumours. These are considered to be of uncertain malignant potential, and as with all Spitz naevi, should be completely excised with margins as for melanoma if sufficiently atypical, and followed up clinically. It is worth reiterating that melanomas may be misdiagnosed as Spitz naevi and vice versa, even by experts, and that some Spitz lesions defy accurate diagnosis by current methods. In recent years, molecular advances have allowed the reclassification of two lesions, HRAS-mutated Spitz naevi and BAPomas, as benign lesions. These had been previously placed in the 'atypical Spitz tumour' category based on histological features alone.

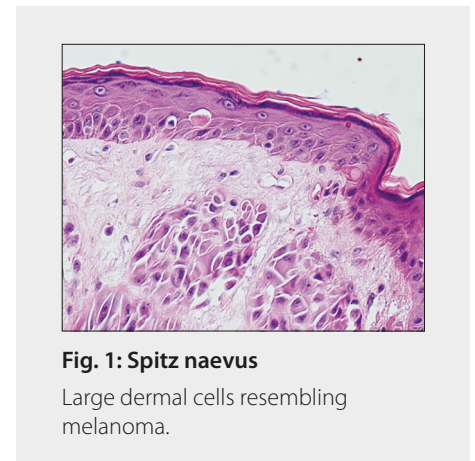


Fig. 1: Spitz naevus

Large dermal cells resembling melanoma.

PIGMENTED SPINDLE CELL NAEVUS

Pigmented spindle cell naevus (Reed naevus), which is no longer considered a variant of Spitz naevus, is a benign naevus that presents particularly on the thighs of young females as a darkly pigmented lesion.

CONGENITAL MELANOCYTIC NAEVUS

Congenital melanocytic naevi occur in 1% of all newborns, and congenital naevus-like naevi/early-onset naevi develop by the age of two years and may be even more common. Small (less than 1.5 cm) and medium-sized (between 1.5 and 19.9 cm) congenital naevi probably have a slightly increased risk of malignant degeneration when compared to acquired naevi, although the degree of the risk is controversial. Studies have shown a risk from 1 to 8%, with a recent review finding that it is 0.7%.

A rate of malignant degeneration of 5% has been estimated for giant (over 20 cm) congenital naevi and in one study 50% of melanomas occurred before puberty. The issues of surgical management and clinical follow-up, therefore, require early specialist consultation.

DERMAL DENDRITIC MELANOCYTIC LESIONS

Dermal dendritic melanocytic lesions are derived from melanocytes whose embryonic migration from neural crest to epidermis has arrested in the dermis. The prototypic lesion is the blue naevus, its colour attributable to the site of pigment deep within the dermis. The common blue naevus is a small blue or blue-black macule or papule occurring at any site. The cellular blue naevus is a larger nodular lesion occurring particularly on the buttocks, extremities, scalp and dorsal aspects of the hands and feet. The Mongolian spot is the most common congenital dermal melanocytic lesion.

These lesions are all benign and the major pathologic issue that (rarely) arises is separation from the rare malignant blue naevus and blue naevus-like metastatic melanoma.

The deep penetrating naevus is regarded by some experts as a variant of blue naevus. It is heavily pigmented, usually occurs in young adults and may have histological features that overlap with Spitz naevus and melanoma.

CLINICALLY ATYPICAL NAEVI

Common naevi can appear atypical clinically and, conversely, some clinically banal naevi can show histological features of dysplastic naevi*. The correlation between clinical and histological findings for atypical/dysplastic naevi is poor to fair.

Various other variants of melanocytic naevi may show atypia clinically or histologically that may be suspicious for melanoma. These include **naevi of special sites** (acral, genital, breast, ear, flexures, umbilicus and perianal region), **irritated naevi**, **regenerating naevi** (after incomplete excision or trauma), **naevi in pregnancy** (which may darken and show a slight increase in mitoses) and **cellular nodules in congenital naevi**. It is therefore important to provide clinical details since a degree of atypia is appropriate in some naevi and does not indicate malignancy.

*Refer to 556 Atypical Pigmented Lesions - Dysplastic Naevi section for further discussion.

Dr Debra Norris FRCPA; MBBS (HONS)
Pathologist in Charge - Histology
Haematopathologist (member EAHP),
Dermatopathologist
P: (07) 3121 4444
E: DNorris@qml.com.au

Dr Natalie Scott-Young BSc(Hons), MBBS,
FRCPATH (UK)
Consultant Dermatopathologist
P: (07) 3121 4444
E: Natalie.Scottyoung@qml.com.au

Dr David Guard BSc MBBS FRCPA
Consultant Histopathologist
P: (07) 3121 4444
E: DrDavid.Guard@qml.com.au