

Skin Cancer Staging 2018

The 8th edition of the American Joint Committee on Cancer (AJCC) Cancer Staging Manual was published at the end of 2016, with the aim of implementation in 2017. However, in conjunction with other organisations in the cancer care community, the decision was made to delay implementation until 1 January 2018 to allow the necessary infrastructure to be put in place for its use.

In the 8th edition, there are significant changes that affect the staging of cutaneous squamous cell carcinoma (SCC) along with some changes to the staging of malignant melanoma. As the changes pertaining to SCC are quite significant, the parameters have already been incorporated into our day-to-day reporting at QML Pathology. For melanoma reporting, in parallel with the practices of the various specialist melanoma units in Queensland, we will continue to use the 7th edition until the end of 2017.

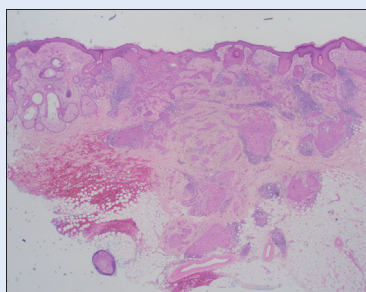
SQUAMOUS CELL CARCINOMA

T-stage	AJCC 7th edition (2010)	AJCC 8th edition (2017)
T1	<2cm, <2HRF	<2cm
T2	≥2cm or any size + ≥2HRF	≥2cm but <4cm
T3	Invasion of orbit, maxilla, mandible or temporal bones	≥4cm or any size with deep invasion or perineural invasion or minor bone erosion
T4	Invasion of skeleton (axial or appendicular) or PNI of skull base	T4a Gross cortical bone/marrow invasion T4b Skull base invasion &/or skull base foramen involvement

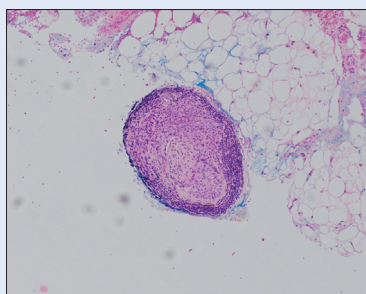
HRF = high risk features

In the 8th edition, staging is only required for cutaneous SCC arising in the head and neck. This includes vermillion lip, but excludes the eyelid as tumours arising in the eyelid are staged separately. The same staging system can be used for other cutaneous cancers of the head and neck, with the exception of Merkel cell carcinoma and melanoma, both of which have their own separate staging systems.

Significant changes have been made to tumour (T) staging. T1 and T2 tumours, which are considered to be low risk tumours, are now defined by tumour diameter (T1 <2cm; T2 ≥2cm but <4cm). Tumours ≥4cm or with high risk features are now placed in the T3 category, with T4 being reserved for bone invasive tumours.



Low magnification of SCC with high risk pattern of perineural invasion seen bottom left corner. Note the 'skip' of just over 1mm between the main tumour and the focus of perineural tumour..



High magnification of perineural invasion.

The high risk features that upstage a tumour have also changed and include any of the following:

- Thickness >6mm (as measured from the granular layer of the adjacent normal epidermis to the base of the tumour)
- Invasion beyond the subcutaneous fat
- Perineural invasion (PNI)*
- Minor bone erosion

*PNI is only significant if any of the following parameters are met:

- Involvement of nerves lying deeper than in the dermis (any size)
- Involvement of dermal nerves measuring ≥0.1mm in diameter
- Clinical/radiological involvement of named nerves

Histological grade/differentiation is no longer used as a high risk feature to stage tumours, but needs to be recorded in the pathology report. Although tumour subtype is not incorporated in staging it also needs to be recorded, making particular note of sarcomatoid or desmoplastic (infiltrative) subtypes as aggressive subtypes.

There are also changes to nodal (N) staging to take into account the significant impact that extranodal extension has on survival.

What should be included in the pathology report?

- Tumour thickness, differentiation and subtype (if applicable)
- Tissue level of invasion
- PNI – including diameter and location of nerves, as well as margin clearance
- Lymphovascular invasion

- Histological margin clearance – acceptable distance is determined by tumour characteristics and the presence of high risk features
- If PNI is present, a comment should be made on whether this is present in a low or high risk pattern and whether specialist referral is recommended

What information should be provided on the request form?

- Tumour location and clinical size
- High risk clinical features (immunosuppression, scar/burn/radiation, nerve pain etc)

MALIGNANT MELANOMA

T-stage	Breslow thickness (mm)
T1	≤1.0mm
T1a	<0.8mm without ulceration
T1b	<0.8mm with ulceration or 0.8-1.0mm +/- ulceration
T2	1.1-2.0mm
T2a	without ulceration
T2b	with ulceration
T3	2.1-4.0mm
T3a	without ulceration
T3b	with ulceration
T4	>4.0mm
T4a	without ulceration
T4b	with ulceration

The main changes in T-staging in the 8th edition include:

- Breslow thickness (BT) measurement is now rounded up or down, to one decimal place
- Histological microstaging of T1:
 - A cut-off of BT 0.8mm and the presence of ulceration is used
 - Mitotic count is no longer used, but is still an important parameter to record

Nodal staging has also changed, whereby non-nodal locoregional metastases** are staged according to the number of concurrent nodal deposits present.

**Definition of non-nodal locoregional metastases:

- Microsatellite: Microscopic metastasis found adjacent/deep to the primary melanoma
- Satellite: Grossly visible cutaneous or subcutaneous metastasis within 2cm of the primary melanoma
- In-transit metastasis: Clinically evident metastasis >2cm from the primary melanoma, in the region between the primary tumour and the first echelon of regional lymph nodes.

What should be included in the pathology report?

Primary melanoma:

- Subtype
- Breslow thickness and Clark level
- Histological Margins
- Regression

For invasive melanoma, the following also need to be recorded:

- Ulceration
- Mitoses
- Tumour infiltrating lymphocytes
- Lymphovascular invasion/angiotropism
- Neural invasion
- Microsatellites
- The presence of a desmoplastic component

Sentinel lymph nodes:

- Presence of metastasis, location and size including isolated tumour cells
- Number of positive nodes
- Detection technique

Who should be offered sentinel lymph node biopsy (SLNB)?

Patients with tumour Breslow thickness >1mm who have no clinical evidence of metastatic disease should be offered SLNB. SLNB should also be considered in patients with tumour BT <0.8mm, but who have high risk features such as mitoses, ulceration or lymphovascular invasion.

SLNB should be performed at the same time as the definitive wide local excision of the primary melanoma as the success rate of identifying the sentinel node is reduced if the patient has already had a wide excision or flap repair.

Dr Debra Norris FRCPA; MBBS (HONS)
Pathologist in Charge - Histology
Haematopathologist (member EAHP)
Dermatopathologist
P: (07) 3121 4444
E: DNorris@qml.com.au

Dr Natalie Scott-Young
BSc(Hons), MBBS FRCPA (UK)
Consultant Dermatopathologist
P: (07) 3121 4444
E: Natalie.Scottyoung@qml.com.au

Dr David Guard
BSc MBBS FRCPA
Consultant Histopathologist
P: (07) 3121 4444
E: DrDavid.Guard@qml.com.au